



University Hospitals
Case Medical Center

Cleveland | Ohio

UH

Innovations In Orthopaedics

Department of Orthopaedics

A 3D medical illustration of a knee joint, showing the femur, tibia, and patella. The joint is rendered in a glowing orange and yellow color. A surgical instrument, possibly a retractor or guide, is visible in the lower left corner. The background features a grid and various geometric shapes, suggesting a technical or scientific theme.

Sarcoma Surgery That Saves Limbs

page 4

3 Excellence in orthopaedics at UH

6 Better outcomes for severe spinal deformities

8 When to refer for spinal surgery

Get Your CME Credits – See Page 7

An Inside Look



Welcome to the premiere issue of *UH Innovations in Orthopaedics*, which allows us to share the outstanding achievements of the clinicians and scientists at University Hospitals Case Medical Center and Case Western Reserve University School of Medicine's Department of Orthopaedic Surgery. Our department is consistently ranked as one of the top orthopaedic departments in the United States. This issue features two of our innovative clinical services that account for this recognition.

■ **Limb-sparing surgery for cancer:** Orthopaedic Oncologic Surgeon

Patrick Getty, MD, routinely performs limb-sparing surgery on patients with

bone or soft-tissue sarcomas. We are one of the few centers in the U.S. performing intraoperative radiation within our state-of-the-art operating rooms. This innovative technique can decrease the risk of tumor recurrence, decrease the risk of surgical complications and shorten the patient's operative time.

■ **Correction of severe spinal deformities:** Pediatric Orthopaedic Surgeon Jochen Son-Hing, MD, is using growing rods, video-assisted thoracoscopic surgery, and posterior spinal fusion with spinal osteotomy to correct severe spinal deformities in pediatric patients. As one of the few centers specializing in these advanced procedures, University Hospitals Rainbow Babies & Children's Hospital has developed a national reputation for the treatment of these conditions.

Our world-class researchers are conducting cutting-edge research on cartilage and bone-cell biology, tissue engineering, biomechanics and functional electrical stimulation. The latest issue of *Case Orthopaedic Journal* highlights some of the exciting research being conducted in our department (the journal is available online at UHhospitals.org/case, keyword "Orthopaedic Journal").

We welcome your comments, questions and suggestions. Feel free to contact us via e-mail or phone, or through our professional referral service.

Randall E. Marcus, MD
Chairman, Department of Orthopaedics
University Hospitals Case Medical Center
Charles H. Herndon Professor
Case Western Reserve University School of Medicine

UH Innovations in Orthopaedics

Contributors: Randall E. Marcus, MD; Patrick J. Getty, MD;
Nancy Hagan, RN, BSN; Jochen Son-Hing, MD;
Publication Coordinator: Rich Riley

Among the nation's leading academic medical centers, University Hospitals Case Medical Center is the primary affiliate of Case Western Reserve University School of Medicine. The Case Western Reserve University School of Medicine is a nationally recognized leader in medical research and education.

UH Innovations in Orthopaedics Fall 2009, Volume 1, Issue 1, is published biannually by University Hospitals for physicians and should be relied upon for medical education purposes only. It does not provide a complete overview of the topics covered and should not replace the independent judgment of a physician about the appropriateness or risks of a procedure for a given patient.

UHhospitals.org. © 2009 University Hospitals in Cleveland, Ohio. All rights reserved.
Produced by McMurry. Contents of this publication may not be reproduced without the express written consent of University Hospitals.



The commitment to exceptional patient care begins with revolutionary discovery. Faculty at the Case Western Reserve University School of Medicine, who also are physicians at UH Case Medical Center, are at the forefront of medical research and innovation. The School of Medicine is the largest medical research institution in Ohio and among the nation's top medical schools for research funding from the National Institutes of Health.

Among the nation's leading academic medical centers, University Hospitals Case Medical Center is the primary affiliate of Case Western Reserve University School of Medicine. The Case Western Reserve University School of Medicine is a nationally recognized leader in medical research and education.


Case Orthopaedic Journal Highlights

The 2008 *Case Orthopaedic Journal* features scientific manuscripts focusing on breakthroughs and advances taking place at University Hospitals Case Medical Center's Department of Orthopaedic Surgery, as well as research breakthroughs from the Case Western Reserve University School of Medicine faculty.

Read the Journal

The journal is available online at UHhospitals.org/case, keyword "Orthopaedic Journal."

Published annually by the department's residents, this issue is dedicated to Dwight T. Davy, PhD, Professor of Orthopaedic Surgery and Mechanical and Aerospace Engineering at Case Western Reserve University. Dr. Davy's innovative work in the design and mechanics of orthopaedic implants



has advanced joint replacement and the treatment of other orthopaedic conditions. This includes groundbreaking research on in vivo hip force analysis using telemetrized implants in the late 1980s.

A Tradition of Excellence in Orthopaedics

The Department of Orthopaedic Surgery at University Hospitals Case Medical Center and the faculty at Case Western Reserve University School of Medicine have a long tradition of clinical and research excellence. The department:

- Is one of the oldest orthopaedic practices in the U.S.
- Was established in 1907, 26 years before the American Academy of Orthopaedic Surgeons and 27 years before the American Board of Orthopaedic Surgery
- Ranks sixth in NIH funding among orthopaedic departments nationwide (2008)
- Is consistently among America's Best Hospitals, ranked in the top 20 for orthopaedic departments by U.S. News & World Report
- Has a coveted orthopaedic residency training program, with 503 applications for six places (2008)

High Honors for Team Members

Congratulations to **Daniel L. Master, MD**, Orthopaedic Resident, and his co-authors **Tom Cowan, MS**; **Sreenath Narayan, MS**; **Robert Kirsch, PhD**; and **Harry Hoyen, MD**; who won this year's Orthopaedic Rehabilitation Association's Jacquelin Perry Award for excellence in research conducted by a resident or fellow.

Additionally, their work also received the Mayfield Basic Science Award from the American Association of Neurologic Surgeons at their annual meeting in Phoenix, Ariz. The title of their project was "Involuntary, Electrically Excitable Nerve Transfer for Denervation: Results from an Animal Model."

Congratulations also to **Richard E. Grant, MD**, Professor and Edgar B. Jackson Chair for Diversity, who won the J. Robert Gladden Society's Alvin H. Crawford Mentoring Award at this year's annual meeting of the American Academy of Orthopaedic Surgeons. Dr. Grant was also the graduation speaker for the Student National Medical Association in Cleveland, Ohio.

Improved Function for Sarcoma Patients

Limb-sparing surgery is standard care at University Hospitals Case Medical Center



Patrick J. Getty, MD, Medical Director, Musculoskeletal Oncology, University Hospitals Case Medical Center

When the pain in her left knee from a fall at a roller-skating party didn't go away, Brittany Huler had an X-ray at University Hospitals Case Medical Center. That film, a subsequent biopsy and staging studies revealed that the 15-year-old from Painesville, Ohio, had localized osteo-sarcoma of the distal left femur.

Orthopaedic Oncologist **Patrick J. Getty, MD**, Medical Director, Musculoskeletal Oncology, University Hospitals Case Medical Center, and Assistant Professor, Department of Orthopaedic Surgery, Case Western Reserve University School of Medicine, recommended limb-sparing surgery with neoadjuvant chemotherapy.

"Limb-sparing surgery provided the best balance of an excellent tumor operation and optimal function," Dr. Getty says.

THE PATIENT IS AT THE FOREFRONT

After Huler completed preoperative chemotherapy, Dr. Getty performed resection with endoprosthetic reconstruction. On Feb. 11, 2009, he resected the distal femur, the soft tissue mass, the biopsy track and a cuff of normal tissue to act as a wide margin. Then he created a custom prosthesis using high-performance, modular endoprosthetic implant components. This gave Huler immediate stability and allowed for quicker rehabilitation than allograft or allograft-prosthesis composite reconstruction. Endoprosthetic reconstruction is associated with fewer complications and is more durable than other types of reconstruction, Dr. Getty says.

Three months postsurgery, Huler was walking without a brace or crutches, and undergoing adjuvant chemotherapy and physical therapy. When recovering at home, she spent time with family and friends and even continued to shop for and spend time with the older women who lived in the apartments behind her high school, through the YMCA Grocery Connection program.

"A lot changed since I was diagnosed with cancer, but I'm still me," Huler says. "I enjoy every day and don't take anything for granted."

"We're expecting Brittany to live a long and full life," Dr. Getty says.

WHY LIMB-SALVAGING SURGERY IS SUPERIOR

Advances in imaging, the design and construction of endoprostheses, adjuvant chemotherapy for bone sarcomas and adjuvant radiation therapy for soft-tissue sarcomas have made limb-sparing surgery the standard of care for most sarcoma patients at UH Case Medical Center. This technique is recommended in cases like Huler's where the surgeon can obtain a wide surgical

margin and preserve the limb's function. The most common contraindication is extensive involvement of the neurovascular bundle.

There is no difference in overall survival between sarcoma patients who undergo this procedure versus those treated by amputation, according to the National Cancer Institute. Long-term sarcoma survivors who have had limb-sparing surgery will likely require revision surgery. However, long-term amputees often require revision surgery as well.

"The major upside of limb-sparing surgery is that you keep your own [body part], and typically return to all activities of daily living. People don't know that you're a cancer patient," Dr. Getty says.

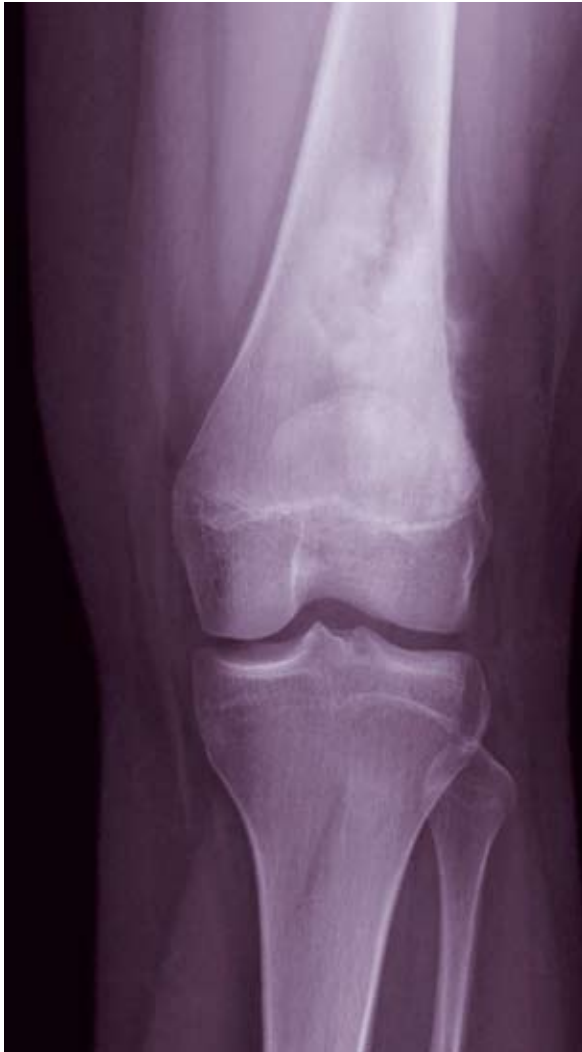"Limb-sparing surgery provided the best balance of an excellent tumor operation and optimal function."

EXPANDING THE BOUNDARIES OF SARCOMA TREATMENT

In cases where a wide surgical margin is not possible because of anatomical constraints, particularly sarcomas in the hand or foot, UH Case Medical Center offers intraoperative radiation therapy to decrease the risk of local recurrence after a limb-sparing procedure. Intraoperative radiation therapy delivers a higher, more targeted dose of radiation than conventional external radiation therapy, with less damage to adjacent healthy tissues, Dr. Getty says.

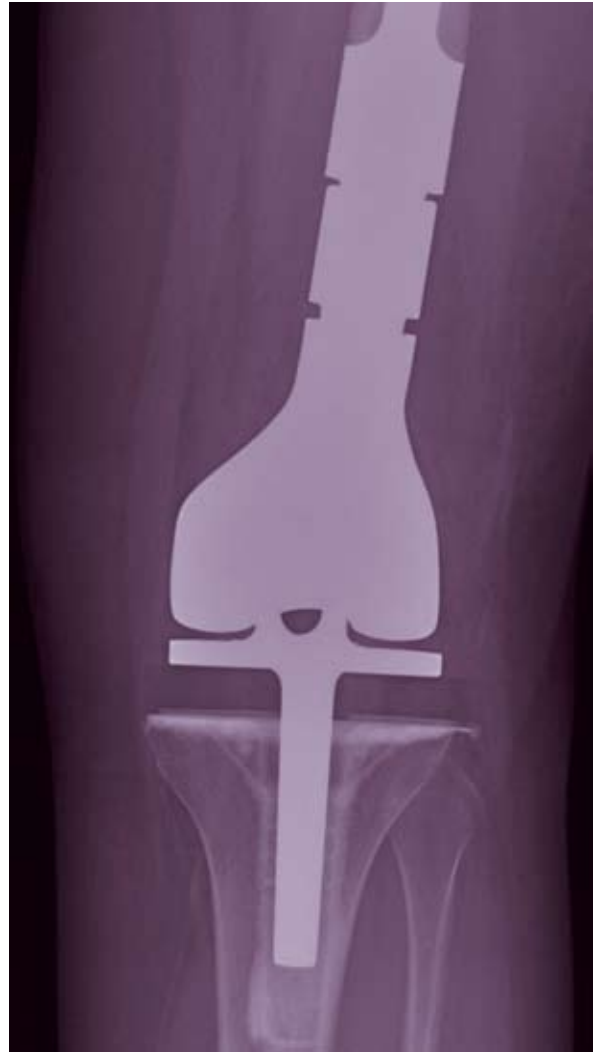It can facilitate limb-sparing surgery in cases that would otherwise require amputation because of proximity to the nerves. University Hospitals Case Medical Center is one of a handful of hospitals in the U.S. that performs intraoperative radiation therapy in the operating room.

For inoperable tumors or patients who cannot tolerate surgery, University Hospitals Case Medical Center offers CyberKnife® radiosurgery, which delivers a higher dose of radiation than is possible with conventional external radiation therapy while limiting exposure of normal tissue. The robotic CyberKnife has a compact linear accelerator and an image guidance system that uses fiducial markers



presurgical

A look at the patient's compromised distal left femur before surgery to remove the osteo-sarcoma.



postsurgical

Patrick Getty, MD, and his team were able to avoid amputation of the leg by performing a limb-salvaging surgery.

implanted around the tumor by interventional radiologists to target the radiation. Surgeons and radiation oncologists work together to plan the treatment.

For younger patients, a group with unique challenges, University Hospitals Case Medical Center has mastered the use of expandable prostheses and allograft reconstruction in skeletally immature patients.

ADVANCES IN ENDOPROTHESES FOR YOUNGER PATIENTS

The development of an expandable implant and modular implants has facilitated the use of limb-sparing surgery in sarcoma patients of all ages.

In a skeletally immature sarcoma patient, a conventional endoprosthesis would require annual, invasive surgeries to increase limb length. Each procedure carries a risk of infection and requires painful rehabilitation.

Expandable implants allow orthopaedic oncologists to maintain equal limb length noninvasively while the patient is growing.

“Providing noninvasive incremental lengthening using electromagnetic fields is the biggest recent development in endoprosthesis technology,” Dr. Getty says.

Periodic treatments with electromagnetic fields expand a compressed spring in the implant, lengthening it internally in small increments. Each expansion takes about 10 minutes to perform. The patient has good range of motion immediately following the procedure.

Each implant is custom-designed. These implants are FDA-approved for the distal femur and the proximal tibia; under Compassionate Use Guidelines, they are also available for the proximal femur, total femur and humerus.

Modular implants for the femur, tibia and humerus in many sizes and with many features enable surgeons to create a custom endoprosthesis intraoperatively for each patient. The use of strong, lightweight materials such as cobalt chrome alloy and titanium and improvements such as rotating knee hinges and cementless stem options have also increased their durability, Dr. Getty says.

“These improvements are increasing the survival of reconstructions,” Dr. Getty says.

Hope for Kids with Spinal Deformities

Advanced procedures promote spine growth and are more tolerable



Jochen Son-Hing, MD, Pediatric Orthopaedic Surgeon, University Hospitals Rainbow Babies & Children's Hospital

Traditional surgical techniques for pediatric patients with severe spinal deformities can cause unfavorable effects on the development of the thorax, lungs and trunk, as well as increased pain and morbidity, according to the Scoliosis Research Society.

Orthopaedic surgeons at University Hospitals Rainbow Babies & Children's Hospital are using advanced surgical techniques: growing rods, video-assisted thoracoscopic surgery (VATS) and posterior-only spinal fusion with spinal osteotomy to correct severe spinal deformities in an attempt to minimize the negative sequelae of more traditional techniques.

With these advanced surgical techniques, the team is successfully treating patients with idiopathic scoliosis and a high-magnitude curve who are under the age of 10, as well as pediatric patients with severe spinal deformities who have an underlying neuromuscular disorder (e.g., cerebral palsy, spina bifida or neurofibromatosis). Although these patients are usually asymptomatic, it is crucial to treat them because once the spinal curve reaches about 45 degrees, it will continue to progress, and is likely to interfere with cardiac and respiratory function.

In patients who are not candidates for growing rods, VATS and posterior-only spinal fusion, University Hospitals Rainbow Babies & Children's Hospital orthopaedic surgeons perform traditional spinal fusion procedures. See the case study on the next page.

PROMOTING SPINAL GROWTH IN YOUNG PATIENTS

Growing rods, a good treatment option for young patients with high magnitude curves and those with a severe spinal deformity because of an underlying neuromuscular disorder, allow the spine to continue to grow, according to the Scoliosis Research Society. The procedure, usually done around age 6, involves a posterior approach and the insertion of one or two rods under the back muscles. The rods are attached above and below the spine's curve with hooks or screws.

"Every six months or so we'll expand the rod until they reach their skeletal maturity, when we convert them to the definitive procedure with multiple fixation points," says **Jochen Son-Hing, MD**, Pediatric Orthopaedic Surgeon, UH Rainbow Babies & Children's Hospital, and Assistant Professor, Orthopaedics, Case Western Reserve University School of Medicine.

This is done through a small incision, usually as an outpatient procedure, Dr. Son-Hing says. The final age is generally between 12 to 14 in girls and 14 to 16 in boys.

Dr. Son-Hing and other orthopaedic surgeons at University Hospitals Case Medical Center are among the most experienced in the country in performing growing rod procedures. "Unlike treatment options such as casting and halo traction, growing rods enable pediatric patients to integrate easily into school and their social environment," Dr. Son-Hing says.

UH Case Medical Center is one of the few centers in Ohio that offers VATS for anterior-only spinal fusion in scoliosis.

FEWER OPERATIONS ARE REQUIRED

The correction of severe spinal deformities has traditionally required an open anterior procedure through a large thoracotomy incision, in addition to a posterior procedure. Orthopaedic surgeons at UH Case Medical Center are using minimally invasive VATS instead of a thoracotomy, as well as posterior-only approaches with spinal osteotomy.

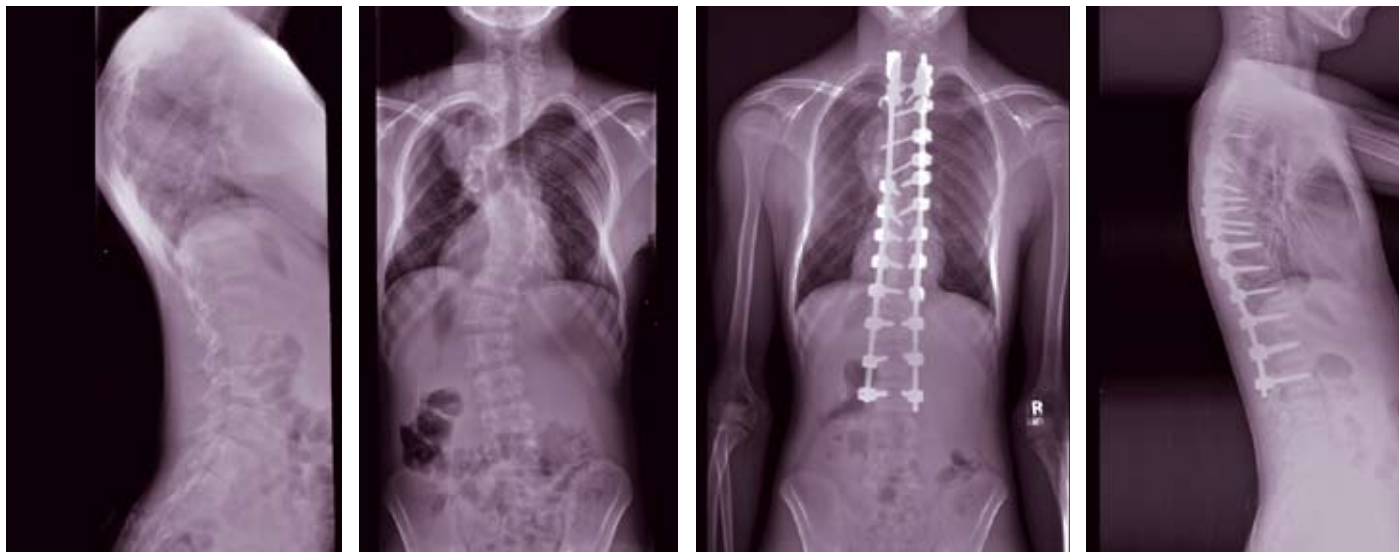UH Case Medical Center is one of the few centers in Northeast Ohio that offers VATS, a technically demanding procedure, for anterior-only spinal fusion in scoliosis. "VATS is a reasonable alternative to thoracotomy for severe curves that affect the thoracic part of the spine where we need to improve the flexibility of the curve," Dr. Son-Hing says.

The minimally invasive procedure enables surgeons to improve flexibility of the spinal deformity through several portals of 2-3 centimeters. Advantages include far less deficit in lung function at medium- to long-term follow-up than with thoracotomy, and less pain and morbidity during recovery.

Spinal osteotomy as part of posterior spinal fusion enables surgeons to increase the spine's flexibility in appropriate candidates. University Hospitals Case Medical Center is one of a number of specialized centers that do this procedure regularly in pediatric patients.

Fusion of Success

A UH Case Medical Center physician finds an alternative when VATS is not an option



Left and left-center: Neurofibromatosis scoliosis in a 13-year-old boy. Right-center and far right: After a staged anterior and posterior spinal fusion with interim halo traction, the boy's spinal deformity was much improved.

A 13-year-old boy with neurofibromatosis, a genetic hamartomatous disorder that often causes spinal deformities, was presented to University Hospitals Rainbow Babies & Children's Hospital with a severe acute curve over a few levels of the spine.

Pediatric Orthopaedic Surgeon **Jochen Son-Hing, MD**, evaluated the patient with a comprehensive history and physical examination, including a neurological assessment, and ordered X-rays, CT scan and MRI. The evaluation revealed a curve of 75 degrees of scoliosis and 75 degrees of kyphosis.

Although the spinal deformity made the patient shorter than his peer group, causing embarrassment, he was otherwise asymptomatic. "He was doing well, but, if the spinal deformity progressed, it could have compromised his spinal cord and neurological function," Dr. Son-Hing says.

EVALUATION

The patient was not an appropriate candidate for VATS or posterior-only spinal fusion. The short, sharp curve would have made access with VATS

difficult. A posterior-only approach would have had a higher risk of a CSF leak because patients with neurofibromatosis often have dural ectasia. The anterior approach was more feasible because of the patient's significantly increased risk for nonunion.

"Obtaining as good a fusion as possible from the front over multiple segments is felt to be advantageous in obtaining a solid fusion," Dr. Son-Hing says.

TREATMENT

In the summer of 2008, Dr. Son-Hing performed staged anterior and posterior spinal fusion with segmental instrumentation and halo-gravity traction to improve the flexibility of the spine before each procedure. Four months after the second procedure, the patient was pain-free and back to his full activities. He had no neurological abnormalities and had markedly improved coronal and sagittal balance. He was also 4 inches taller.

"It's rare to get that much improvement," Dr. Son-Hing says. "This is an extraordinary outcome."

Milestones in Surgery for Severe Spinal Deformities

Instrumentation in Spinal Fusion

- Nonsegmental spinal instrumentation: Harrington procedure, mid-1950s
- Segmental spinal instrumentation: starting with the Cotrel-Dubousset procedure, mid-1980s

Surgical Techniques

- Video-assisted thoracic surgery: mid-1990s
- Growing rods (current method): early 1990s
- Spinal osteotomy: Smith-Peterson procedure, 1945; increased use of more complex procedures, early 2000s

Sponsored by:



Earn CME Credits

Hear more about cases like these and receive CME credits from Case Western Reserve University School of Medicine. Go to UHhospitals.org/case, keyword "CME" for a listing.



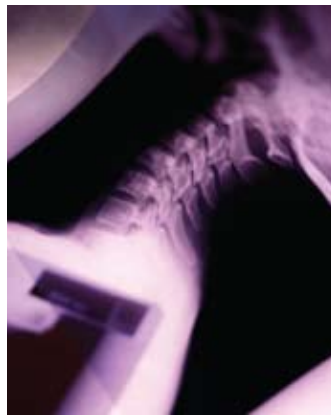WHEN TO REFER/GRAND ROUNDS

Call Our Spine Surgery Experts

The duration and severity of pain are major determinants for referral to the spine surgeons at the Department of Orthopaedic Surgery at University Hospitals Case Medical Center. Patients with persistent pain lasting more than several weeks, especially pain that has not responded to conservative management, should be considered for referral. Physicians should consider referring for further evaluation those patients with:

- Intractable or disabling pain in their back or extremities.
- Extremity weakness.
- History of prior surgery who have ongoing or new symptoms.
- Signs and symptoms of spinal cord compression (myelopathy).

Neuroradiologists provide expert evaluation of MRIs and myelograms to assess spine conditions ranging from spinal cord tumors to herniated discs. University Hospitals spine experts specialize in surgery for



complex conditions such as spinal cord compression, in which they use intraoperative spinal cord monitoring, and revision lumbar spine surgery.


CONDITIONS WE TREAT

- Degenerative and acquired conditions of the cervical, thoracic and lumbar spine.
- Disc herniations and spinal stenosis.
- Severe spinal cord compression with myelopathy and paralysis.

Grand Rounds

- **Oct. 27-28:** Carter-Makley Visiting Professorship
"Diagnosis and Prognosis of Soft Tissue Sarcomas"
Sharon W. Weiss, MD
Professor, Pathology & Laboratory Medicine
Associate Dean, Emory University School of Medicine
Atlanta, Georgia
- **June 15-16, 2010:** Case Orthopaedics Resident
Research Visiting Professorship
"What's New in Hand Surgery"
Peter J. Stern, MD
Norman S. & Elizabeth C.A. Hill Professor & Chairman,
Department of Orthopaedics,
University of Cincinnati College of Medicine
Cincinnati, Ohio

For further information about these events, held at the Wolstein Research Building Auditorium, including directions, please contact Ellen Greenberger, Education Coordinator, Department of Orthopaedics, at **216-844-3233**, or **Ellen.Greenberger@UHhospitals.org**.



Nancy Hagan, RN, BSN

Orthopaedic Triage Referrals

Clinical Nurse Manager Nancy Hagan, RN, BSN, answers physicians' questions, triages patients and ensures that appointments are made within 48 hours when necessary. Call **216-844-7200** to access orthopaedic specialists and refer patients to University Hospitals Case Medical Center's Department of Orthopaedic Surgery.