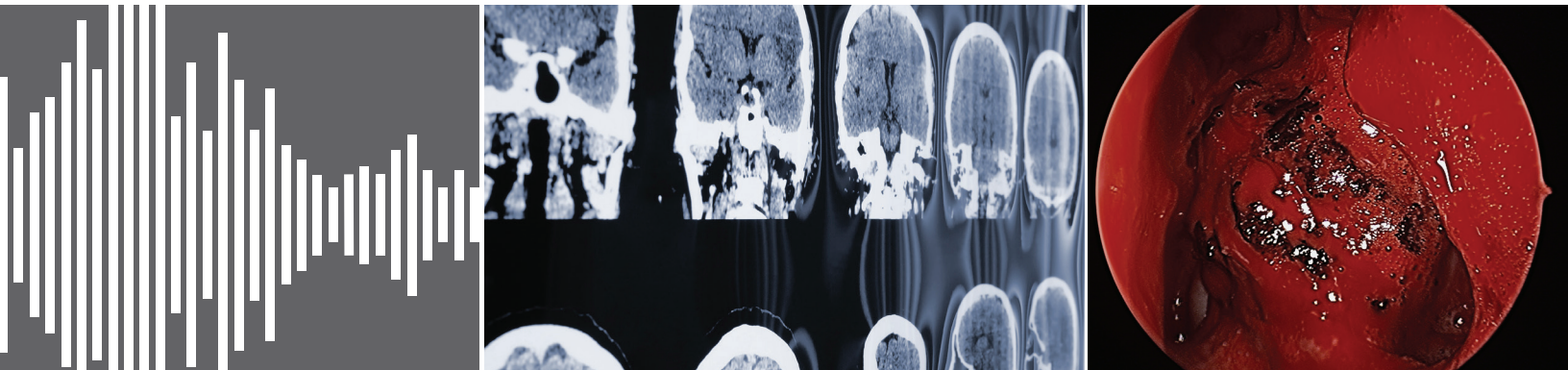


INNOVATIONS IN OTOLARYNGOLOGY – HEAD & NECK SURGERY



Sound Solution
**Pediatric auditory
brainstem implantation (ABI)**
pages 4 – 5

3
Institute News

6
Endonasal Excellence

7
Making Headway
in Uganda

ENT: Growing Service Line Capacity for the 21st Century

Across the United States, many major hospital systems and medical centers are growing as a result of consolidation in the health care industry. Many are also expanding their market share through the growth of accountable care organizations (ACOs), managing large numbers of patients according to the principles of population health. At University Hospitals in Cleveland, our ACOs now provide care for nearly 300,000 patients across 15 Ohio counties.

Here in Northeast Ohio, individual ENT specialists are increasingly being asked to work with or within these large systems. However, there can be bumps in the road. Patient demand for ENT services within these large networks often outstrips the capacity of a traditional ENT department, with its core faculty almost exclusively dedicated to the tertiary academic medical center.

At UH, we're addressing this challenge by rethinking the traditional model of what an otolaryngology department should be. We've established relationships and affiliations with dozens of ENT practices throughout Ohio, partnering with them on GME and CME and providing real-time consults via mobile phone or Skype. They know us, and we know them. These practices remain independent, but they have us as backup. Together, we manage patients in our ACOs, allowing individual ENT specialists to meet their patients' needs for care close to home, while giving these new partners expedited access to the tertiary and quaternary resources of a leading academic medical center.

At the same time, we're adding fully employed ENT specialists to our ranks in our surrounding communities, including eight new community otolaryngologists in the past few years. The key to this success is an economic model that makes sense at the community level, with appropriate duties, responsibilities and metrics for success. These new partners get the best of both worlds – providing close-to-home care to their patients in their communities, while participating in the quality metrics, robust electronic health system and attention to population health management that have made UH ACOs so successful.

Going forward, another option we're offering ENT specialists is becoming part of a clinically integrated network. These physicians will not be employed by UH, but will be partners in quality and patient satisfaction, participating in the narrow-network contracts entered into by our large organization.

The goal of all these initiatives is to expand the reach of vital services we offer, providing not only expertise but true access for our growing population of patients. It's our blueprint for growing ENT capacity given the new realities of 21st century health care.

Warm regards,



CLIFF MEGERIAN, MD

*Chair, Otolaryngology – Head & Neck Surgery,
University Hospitals Case Medical Center
Director, UH Ear, Nose & Throat Institute
Richard W. and Patricia R. Pogue Chair in
Auditory Surgery and Hearing Sciences
President, University Hospitals Physician Services
Professor of Otolaryngology,
Case Western Reserve University
School of Medicine*

For more information from University Hospitals, visit **UHDoctor.org**. This new online resource center features relevant content for physicians and other clinicians, covering clinical practice, patient care, research and education. Visit UHDoctor.org today!



The commitment to exceptional patient care begins with revolutionary discovery. University Hospitals Case Medical Center is the primary affiliate of Case Western Reserve University School of Medicine, a national leader in medical research and education and consistently ranked among the top research medical schools in the country by U.S. News & World Report. Through their faculty appointments at Case Western Reserve University School of Medicine, physicians at UH Case Medical Center are advancing medical care through innovative research and discovery that bring the latest treatment options to patients.

Institute News



Maroun Semaan, MD, Elected to the Triological Society

University Hospitals head and neck surgeon Maroun Semaan, MD, has been elected to the Triological Society, the most prestigious society in otolaryngology. Dr. Semaan is Associate Director of Otolaryngology and Neurotology and Director of the Cochlear Implant Program at UH Case Medical Center and the UH Ear, Nose & Throat Institute, as well as Assistant Professor of Otolaryngology at Case Western Reserve University School of Medicine.

Dr. Semaan is a native of Beirut, Lebanon. After completing medical school at Universite St. Joseph, he came to the United States to pursue a career as an otolaryngologist. He completed his residency training in general surgery and otolaryngology at UH Case Medical Center and completed fellowship training in otology and neurotology at the House Ear Clinic in Los Angeles, California.

Dr. Semaan is a Fellow of the American College of Surgeons. He is involved in resident and medical school teaching and has authored and co-authored more than 50 peer-reviewed publications and textbook chapters. His research interests and clinical expertise include Meniere's disease, skull base surgery, hearing loss and cochlear implantation.

Institute Researcher Secures \$1.5 Million NIH Grant

UH Ear, Nose & Throat Institute scientist Brian McDermott, PhD, has been awarded a \$1.5 million, five-year grant from the National Institutes of Health to study the role of a newly identified protein that may govern the formation of hair cells in the inner ear and lateral line system. The grant is administered through Case Western Reserve University School of Medicine, where Dr. McDermott is Assistant Professor of Otolaryngology, Neuroscience, and Genetics and Genome Sciences.



The new protein is called ACF7.

"With this new grant, we aim to understand the role of this protein in hearing," Dr. McDermott says. "The precise morphology of the mechanosensitive hair bundle requires seamless integration of actin and microtubule networks. We've identified Acf7a as a protein positioned to bridge these distinct cytoskeletal networks in hair cells."

Dr. McDermott has imaged Acf7a-Citrine fusion protein in zebrafish, which have hair cells very similar to human hair cells. He's also done immunolabeling of vestibular and cochlear mouse hair cells.

"In this work, we've shown that Acf7a and ACF7 circumscribe, underlie and are interwoven into the cuticular plate (CP), and they also

encircle the basal body of the kinocilium. During hair cell development and regeneration, Acf7a precedes formation of the hair bundle and CP."

According to Dr. McDermott, electron tomography shows that the ends of microtubules insert into the CP and are decorated with filamentous linkers connecting microtubules to the CP.

"These observations are consistent with ACF7 being a linker protein, which may shape the hair cell's cytoskeleton early during hair-bundle genesis," he says.

For more information about this work, email Dr. McDermott at bmm30@case.edu.

New Physicians Join UH Ear, Nose & Throat Institute

Akron ENT Associates, Inc., the practice of board-certified otolaryngologists Kenneth E. Mooney, DMD, MD, and Steven L. Kutnick, MD, recently became part of the University Hospitals Ear, Nose & Throat Institute.

Dr. Mooney completed his dentistry degree, medical degree and otolaryngology residency at the University of Pennsylvania. Dr. Kutnick earned his medical degree at the University of Michigan. He completed a residency in general surgery at John H. Stroger, Jr. Hospital of Cook County (Illinois) and completed his otolaryngology residency at Northwestern Memorial Hospital. Both Dr. Mooney and Dr. Kutnick serve as clinical assistant professors at Northeast Ohio Medical University (NEOMED).

UH ENT specialists Nicole Fowler, MD, Todd Otteson, MD, Nicole Maronian, MD, and Diana Ponsky, MD, also now provide services at Akron ENT Associates, Inc.

The UH Ear, Nose & Throat Institute also welcomes board-certified otolaryngologist Mark Guay, MD. Dr. Guay is Director of the Center for Otolaryngology at UH Sheffield Health Center.

Dr. Guay completed his medical degree at the Stritch School of Medicine at Loyola University in Chicago. He completed residency training in otolaryngology at Cleveland Clinic.

Auditory brainstem implantation (ABI) surgery has typically been reserved for adult patients with bilateral vestibular schwannomas caused by neurofibromatosis type 2 (NF-2), as a means of restoring hearing. However, over the past 10 years, indications for the procedure have evolved. Although pediatric ABI surgery is still being studied in clinical trials, specialists are increasingly offering the procedure to pediatric patients and their families.

“ABI surgery is now indicated for people who were born deaf or with profound hearing loss, either because they never had cochleas develop or have only small, rudimentary remnants of cochleas that cannot receive a cochlear implant,” says Maroun Semaan, MD, Director of Otolaryngology and Neurotology at University Hospitals Ear, Nose & Throat Institute. “ABI surgery is now also indicated for those who were born without an auditory nerve (cochlear nerve aplasia) or a very thin auditory nerve (cochlear nerve hypoplasia).”

A multidisciplinary team at UH recently had the opportunity to put these expanded indications into practice. Dr. Semaan, UH Ear, Nose & Throat Institute Director Cliff Megerian, MD, neurosurgeon Nicholas Bambakidis, MD, and audiologist Gail Murray, PhD, CCC-A, provided an auditory brainstem implant to a 14-year-old girl born without cochleas – the first pediatric patient in Ohio to undergo such a procedure.

The patient had developed language using the total communication approach of voicing and American Sign Language and had used a vibrotactile device for picking up on environmental cues. “She had a really nice foundation when it came to language,” Dr. Murray says. “It made it much easier to work with her and explain concepts for her to understand and follow.”

Before the surgery, Dr. Murray and her audiology team worked with the patient and her family to set reasonable expectations. “We wanted them to understand that this was going to be hard and tedious and would require many visits,” she says. “They all needed to be on board with it. Everyone had to understand what was to come.”

In performing the surgery, Dr. Bambakidis and Dr. Semaan opted for the retrosigmoid approach to reach the brainstem, as opposed to the more traditional translabyrinthine craniotomy. The most challenging test came in placing the internal electrode pad in the correct location on the cochlear nucleus.

“With the ABI, it’s a bit of blind/nonblind technique, where you apply the electrodes on the dorsal surface of the fourth ventricle – the approximate location of the cochlear nucleus,” Dr. Semaan says. “You don’t know exactly where it is, how well developed it is and what to expect. We didn’t really know what was going

to happen when we put that implant in the brainstem. Was the cochlear nucleus still there? Did it develop? Did it degenerate? Was there some neuronal plasticity involved with it being used for nonauditory perception or function?

Fortunately, intraoperative electrical auditory brainstem response (EABR) testing confirmed that the implant was indeed in the right place. “That’s very important,” Dr. Semaan says. “Otherwise we can stimulate nonauditory centers of the brainstem, which can cause side effects that are quite unpleasant and can sometimes be dangerous.”

“When we activated it, we were all happy to see that she had auditory perception without a doubt,” Dr. Semaan adds. “We cheered for her, but we were also very interested from a neurophysiological perspective. Even when you had the end organ not developing, the ‘docking structure,’ in this case, the cochlear nucleus, did not go away, disappear or ramp down. It was there waiting for one day to receive the signal.”



After the internal electrode pad was placed and verified, Dr. Murray and her team tested the ABI on all 20 of its electrode channels. “We kind of bracketed them based on their location on the brainstem,” she says. “When we got response on one, we jumped to another area. We did that regional testing and filled in the gaps afterward.”

The team activated the device about three months post-surgery. The first sound the patient heard was her father’s voice (see sidebar). Intensive sessions to map the patient’s responses to auditory stimuli soon followed.

“The early stages of mapping were for us to see where she had a response, hopefully an auditory one, and then making it comfortably loud,” Dr. Murray says. This testing revealed that four of the 20 channels should be turned off. Some were creating unwanted nonauditory responses, and others were unpleasant to the patient in how they sounded.

Later mapping focused on having the patient rank pitches according to their frequency. “Pitch ranking is the most difficult task,” Dr. Murray says. “The auditory system is organized in a

tonotopic manner, from the inner ear, through the lower brainstem to the cortex of the brain. The goal is to assign the electrodes on the ABI pad the frequency that is perceived and organize the electrodes in a way that best matches the tonotopic organization of the patient's brainstem and auditory pathway.

Auditory brainstem implant restores hearing to normal range for teenager born without cochleas

Solution

"Take the word 'scissors,' which is a high-pitched word," Dr. Murray adds.

"If I don't have the electrodes that are assigned those high frequencies in the area where she perceives it as high frequency, she'll perceive it as something completely different. If we have this sequenced incorrectly, it will impede her ability to start learning the meaning of words."

After many hours of mapping sessions and acclimating to sounds, the patient is now hearing in the normal range. Dr. Murray attributes some of this success to new external speech processor technology. The updated processor is lighter and thinner than its predecessor. Plus, it automatically adjusts the digital sound algorithm based on the needs of the sound environment, without the patient having to manually change programs.

"For me, that's one of the most exciting things," Dr. Murray says. "It's what brought her from mild hearing loss level into normal hearing level. After the first adjustments, I'm sure she heard her dog bark and her father's deep voice, but a lot of different voices, she would not have been able to appreciate unless they were raised and shouting. But now that we're finished mapping, there is a big difference, which is exciting to see. Now her responses are in normal hearing range."

The patient is continuing with auditory verbal therapy to develop listening and speaking skills.

For both Dr. Semaan and Dr. Murray, outcomes like these point to the importance of a multidisciplinary approach to complex issues.

"This work only happens because of the close collaboration of many departments," Dr. Semaan says. "There was a whole team of experts involved, and everybody had to do their best work."

For more information on this case, email Maroun.Semaan@UHhospitals.org or Gail.Murray@UHhospitals.org.



MAROUN SEMAAN, MD

Associate Director of Otolaryngology and Neurotology and Director of the Cochlear Implant Program, University Hospitals Case Medical Center and UH Ear, Nose & Throat Institute Assistant Professor of Otolaryngology, Case Western Reserve University School of Medicine



GAIL MURRAY, PHD, CCC-A

Director of Audiology Services University Hospitals Case Medical Center and UH Ear, Nose & Throat Institute

Patient's Story Reaches Millions

More than 4 million people worldwide have witnessed the moment when the young ABI patient at University Hospitals heard her father's voice for the first time. Digital outlets that published her story include USA Today, Huffington Post, People.com, Daily Mail and CNN. The original video, hosted on University Hospitals YouTube page, generated approximately 900,000 impressions on YouTube alone.

To view the short video, go to

<https://www.youtube.com/watch?v=8Aar9QxJoK4>.

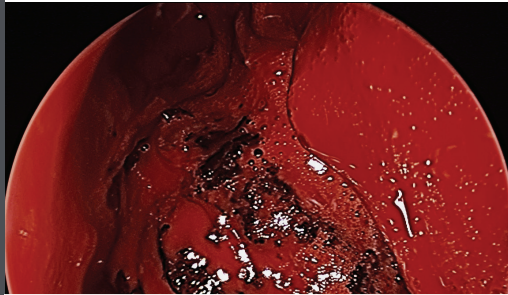
Endonasal EXCELLENCE



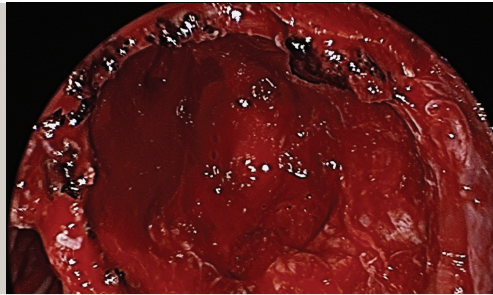
KENNETH RODRIGUEZ, MD

Chief of Allergy, Rhinology/Anterior Skull Base Surgery
University Hospitals Case Medical Center
and UH Ear, Nose & Throat Institute
Assistant Professor of Otolaryngology,
Case Western Reserve University
School of Medicine

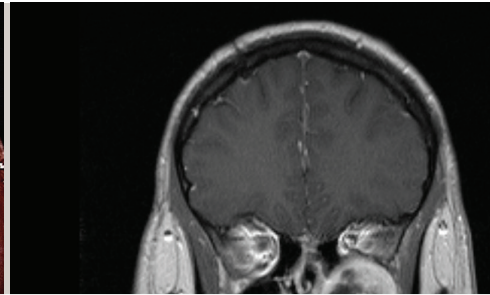
Rare surgery results in great outcome for young NF-2 patient



Endoscopic view of the left nasal cavity. The inferior turbinate has been resected, the maxillary sinus has been opened widely, and the ethmoid cavity has been dissected. The mass is centered within the pterygopalatine fossa with expansion in all orientations.



Post resection view. The posterior wall of the maxillary sinus has been widely opened. Posterioinferiorly are the pterygoid plates and superiorly the lesion was in close approximation to the temporal lobe. Within the anterior superior region of the resection cavity the orbit is dehiscent. The internal maxillary artery was identified and preserved inferiorly.



Coronal T1 post contrast MRI demonstrating the left sided schwannoma centered within the pterygopalatine fossa. Inferior orbital compression is demonstrated.

Neurofibromatosis type 2 (NF-2) is an autosomal dominant syndrome with multiple manifestations, most notably neurologic lesions. "It's rare for masses to develop in the pterygopalatine fossa or infratemporal fossa, but given the neural structures in those regions, it certainly can occur," says Kenneth Rodriguez, MD, Chief of Allergy, Rhinology/Anterior Skull Base Surgery at University Hospitals Ear, Nose & Throat Institute.

Dr. Rodriguez was presented with such a case in April 2015 – a young man with NF-2 who'd previously had surgery at another hospital to remove one of his bilateral acoustic neuromas. The patient complained of left facial pain and pressure, nasal airway obstruction, decreased sense of smell and epistaxis. Imaging demonstrated a left infratemporal fossa/pterygopalatine fossa mass, consistent with a schwannoma.

"It had remodeled the medial wall of the pterygopalatine fossa and floor of the orbit," Dr. Rodriguez says. "It had expanded posteriorly to be lateral to the left sphenoid sinus at the base of the temporal lobe."

Based on these findings and the patient's symptoms, Dr. Rodriguez recommended surgery as the best option.

"Although the lesion appeared radiographically benign, it was likely going to continue to slowly grow over time and cause progression of symptoms," Dr. Rodriguez says. "What makes these tumors very interesting is that they slowly expand and can displace normal structures. Given the proximity to his orbit, he could begin to experience double vision as his eye was slowly displaced superiorly. There was also a small chance of the lesion degrading into malignancy."

To resect the tumor, Dr. Rodriguez and his team opted for an endonasal approach. "Normal endoscopic sinus surgery is all about preserving normal structures," Dr. Rodriguez says. "The problem is when you're doing tumor surgery, you need wide access. If you get into bleeding, you can't be in a limited space especially with vessels like the internal maxillary artery. To gain wide exposure, we did an endoscopic medial maxillectomy approach involving resection of the inferior turbinate, lacrimal bone and medial maxilla to be able to take a 0 degree scope, put it in the nostril, turn it to the side and see the entire back wall of the maxillary sinus straight on.

"When the tumor was grossly resected, the patient's orbital floor was basically free-floating because of bone loss from compression by the tumor," Dr. Rodriguez adds. "However, with the periorbita intact, his eye maintained normal position following resection."

There was no leak of cerebrospinal fluid following surgery, and the internal maxillary artery was identified and was left intact. His pathology was schwannoma, and following recovery, the patient's symptoms resolved. He did not develop "empty nose syndrome," which can occur after aggressive endonasal surgery, and he did not develop numbness of V2. However, the patient does have some numbness on the left side of his hard palate.

"This makes us suspect the tumor may have originated from one of the sensory nerves going to the hard palate," Dr. Rodriguez says. "It is very gratifying to be able to remove such a large mass via endonasal techniques with minimal morbidity."

For more information on this case, email Kenneth.Rodriguez@UHhospitals.org.

making HEADWAY

Head and neck outreach program in Uganda strengthens undersized health care infrastructure

Citizens of Uganda have virtually no access to ENT specialists and head and neck surgeons.

“There are about 15 of these physicians in a country of 33 million people,” says Chad Zender, MD, a head and neck surgeon at University Hospitals Ear, Nose & Throat Institute.

This physician shortage can become a vicious cycle, feeding on itself by driving newly trained otolaryngology specialists away.

“Uganda has one of the largest medical schools in East Africa, but because of infrastructure challenges there, there’s a ‘brain drain’ that occurs,” Dr. Zender says. “Ugandan physicians tend to go to other countries where the medical infrastructure is a little stronger. There’s also the difficulty people have in traveling to the cities where the majority of the otolaryngologists are located. The bottom line is that there’s a huge lack of access and challenge getting to limited number of physicians that are there.”



To address these challenges, Dr. Zender and his nurse partner, Katrina Harrill, RN, lead a group of ENT specialists from UH and Case Western Reserve University School of Medicine to Uganda twice a year for two-week surgical camps. The group of about seven typically includes a mix of physicians, nurses, fellows, residents and medical students. During their first trip in November 2014, the team performed 10 surgeries – the first at the Uganda Cancer Institute (UCI) – and provided a cadaver course and lectures to medical students and residents at Makerere University, working with Ugandan head and neck surgeons Jeff Otiti, MD, and Justine Namwagala, MD, and UCI director Jackson Orem, MD.

In May 2015, the team returned and were joined by a group from Vanderbilt University, which was led by James Netterville, MD. Together, they performed 40 operations. In October 2015, the Cleveland group did 30 surgeries. “It runs the gamut,” Dr. Zender says. “Procedures include everything from exams under anesthesia to assess a patient’s airway to removing salivary gland tumors to major, eight-to-10-hour procedures that require removing large jaw tumors and reconstruction with free tissue transplantation. Our fundamental objective is to do good work one patient at a time. The secondary goal of improving health care through physician, resident and nursing education happens with each of these individual patient encounters, which has a truly lasting and global impact.”



The Ugandan outreach effort has its roots in research conducted by UH infectious disease specialist Robert Salata, MD, also Professor of Medicine at the School of Medicine. “That’s how I got interested, by looking at some head and neck research opportunities over there,” Dr. Zender says. “That’s how I met Dr. Otiti.”

Currently, Dr. Zender is pursuing a couple of different research avenues centered on HPV, HIV and head and neck cancer. “As an extension of Dr. Salata’s work in cervical cancer in Africa, we’re working with Dr. Matt Cooney and Dr. Aaron Weinberg, in addition to the Ugandan physicians, to study the incidence of HPV-associated head and neck cancer in Uganda and the different genotypes of strains of HPV that could be involved,” he says. “Are there differences between HIV-positive and HIV-negative individuals? This would also have implications regarding vaccination. However, what started as a research collaboration has evolved into an outreach program that is quite unique, incorporating research, service work and education all in one.”

Funding for the entire outreach effort has come from philanthropic gifts, a grant from the Center for AIDS Research and a gift from UH Ear, Nose & Throat Institute Director Cliff Megerian, MD, which he received from the Healthnetwork Foundation as recipient of its Service Excellence Award. This gift, in particular, has made it possible for ENT residents to make the trip to Uganda.

For Dr. Zender, taking colleagues along is one of the most valuable parts of the program.

“One of the most rewarding aspects is seeing the impact of these trips on the individuals I take over with me, which is really a blessing,” he says. “It allows us all to learn from the Ugandans about the involvement of families and how other societies deal with health care issues. Seeing how involved the patients’ families are in taking care of their loved ones is truly remarkable.”

For more information about the ENT outreach program in Uganda, email Chad.Zender@UHhospitals.org.



CHAD ZENDER, MD

*Head and Neck Surgeon
University Hospitals Case Medical Center
and UH Ear, Nose & Throat Institute
Associate Professor of Otolaryngology,
Case Western Reserve University
School of Medicine*

UNIVERSITY HOSPITALS

Marketing & Communications

MSC 9160

11100 Euclid Avenue

Cleveland, Ohio 44106

COORDINATED CARE FOR COMPLEX ISSUES

Multidisciplinary Pediatric Aerodigestive Clinic a first in the Cleveland area

For children with complex airway, swallowing and breathing issues, the boundaries between medical subspecialties can sometimes be an impediment to receiving the best care.

“Often times, there are conditions such as reflux, airway inflammation and upper airway issues that all go together,” says Jay Shah, MD, a pediatric otolaryngologist at University Hospitals Rainbow Babies & Children’s Hospital. “We believe in a unified airway where the lungs, trachea, esophagus and stomach often work hand-in-hand in making a child’s symptoms worse.”

Treating patients piecemeal, with different visits to different specialists, often doesn’t allow for seeing the whole picture, Dr. Shah says. To improve on this approach, he and colleagues from UH Rainbow Babies & Children’s Hospital’s Departments of Gastroenterology and Pulmonology are launching a new, multidisciplinary Pediatric Aerodigestive Clinic, focused on providing comprehensive care for the most complex aerodigestive cases.

“We’ve created a partnership where we can treat children with complicated airway, swallowing and breathing issues all within one clinic,” Dr. Shah says. “Often, these children need multiple subspecialists. To have them get all their care in one clinic not only improves patient care, it helps with team collaboration and leads to better patient outcomes.”

During a typical visit, the child and his or her family are seen by GI, pulmonology and ENT specialists in succession. The team then meets to develop a care plan, which they share with the family that same day. If the child needs to have additional tests or surgery, the clinic’s care coordinator works with the relevant departments, surgical scheduler and the anesthesia group to make the necessary arrangements.

This approach leads to a better experience for young patients and their families – and more prompt care.

“When you have a patient who needs four different tests from four different specialists, it’s taxing on the families,” says UH Rainbow Babies & Children’s Hospital ENT specialist Todd Otteson, MD, who is also part of the new clinic. “Plus, many of these conditions are time-sensitive. If a child is aspirating, we can’t wait several weeks for a treatment plan.”

Both Dr. Shah and Dr. Otteson believe there is also value in all the specialists being in the same room at the same time. “There’s nothing better than bouncing ideas off a fellow physician,” Dr. Shah says.

For more information about the new Pediatric Aerodigestive Clinic at UH Rainbow Babies & Children’s Hospital or to make a referral, call 216-844-6000.



JAY SHAH, MD

*Pediatric Otolaryngologist
University Hospitals Rainbow Babies & Children’s Hospital and UH Ear, Nose & Throat Institute
Assistant Professor of Otolaryngology and Pediatrics,
Case Western Reserve University School of Medicine*



TODD OTTESON, MD

*Division Chief, Pediatric Otolaryngology, University Hospitals Rainbow Babies & Children’s Hospital and UH Ear, Nose & Throat Institute
Associate Professor of Otolaryngology and Pediatrics,
Case Western Reserve University School of Medicine*



In 2015, UH Rainbow Babies & Children’s Hospital again ranked as one of America’s Best Children’s Hospitals in eight pediatric specialties, including #3 in neonatology, #7 in orthopaedics, #11 in pulmonology and #19 in oncology.

Learn more at Rainbow.org/USNews.

Innovations in Otolaryngology Winter 2016

Contributors: Cliff Megerian, MD; Maroun Semaan, MD; Gail Murray, PhD, CCC-A; Kenneth Rodriguez, MD; Chad Zender, MD; Jay Shah, MD; Todd Otteson, MD

Writer: Kelly Kershner Designer: Scott Taylor

Marketing Manager: Rich Riley

Innovations in Otolaryngology is published by University Hospitals for physicians and should be relied upon for medical education purposes only. It does not provide a complete overview of the topics covered and should not replace the independent judgment of a physician about the appropriateness or risks of a procedure for a given patient.

UHhospitals.org © 2015 University Hospitals in Cleveland, Ohio. All rights reserved. Contents of this publication may not be reproduced without the express written consent of University Hospitals.